

# Minimally invasive, robot assisted cochlear implantation

Stefan Weber, Brett Bell,  
Nicolas Gerber, Tom  
Williamson  
ARTORG Center  
University of Bern  
Bern, Switzerland

Peter Brett, Xinli Du  
Brunel Institute for  
Bioengineering  
Brunel University  
London, UK

Marco Caversaccio  
Department of ENT, Head  
and Neck Surgery  
Bern University Hospital  
Bern, Switzerland

David Proops, Chris  
Coulson, Andrew Reid  
Department of  
Otolaryngology  
Queen Elizabeth Hospital  
Birmingham, UK

Cochlear implants allow the restoration of hearing function in patients with severe to profound sensorineural hearing loss through the direct stimulation of the auditory nerve by an electrode array inserted into the inner ear. Typically, access to the cochlea is gained through the performance of a mastoidectomy, which involves the removal of a large portion of the mastoid bone, allowing the surgeon to visualize and protect vital structures within the mastoid during milling. Once access to the cochlea has been achieved, the surgeon may insert the electrode through the round window, or alternatively through an artificial access called a cochleostomy. Recent advances in image guided robotics have allowed dramatic changes in the performance of both stages of this procedure. Recent work at the University of Bern has seen the realization of a robotic system designed specifically for minimally invasive cochlear implantation. The system enables significantly reduced invasiveness by removing the need for a mastoidectomy, replacing this with a direct tunnel approach known as direct cochlear access (DCA). Meanwhile, work at Brunel University has focused on improving the safety and accuracy of inner ear access through the cochleostomy. This work describes both of these systems individually and discusses the implications and opportunities associated with the combination of these devices.

**Keywords**—*cochleostomy; robotics; image guidance; cochlear implant; direct cochlear access*

## I. INTRODUCTION

### A. Minimally Invasive Cochlear Access

Direct cochlear access (DCA) is a minimally invasive method for accessing the inner ear. It involves the drilling of a trajectory directly from the surface of the temporal bone to the cochlea, thereby circumventing the need for a mastoidectomy. The mastoidectomy, which represents the current state of the art for inner ear access, comprises the milling of a large cavity in the mastoid region of the temporal bone, allowing the surgeon to visualize and protect vital structures while gaining access to the cochlea. The realization of a minimally invasive approach is of particular interest considering the diameter of a cochlear implant electrode (typically less than 1.5 mm) when compared to the size of the cavity created during the mastoidectomy. Typically, a DCA trajectory will pass from

the mastoid through the facial recess (formed by the divergence of the facial nerve and chorda tympani) to the round window. While the size of the cavity created by drilling (tunnel diameter 1.5 – 2 mm) is more appropriate considering the size of the electrode to be placed, the anatomy of the facial recess significantly limits the area in which a trajectory can be drilled. It also leads to substantial accuracy constraints: in order to avoid damaging the facial nerve or other anatomy when passing blindly through the facial recess the surgeon must be confident in the position of the drill relative to vital anatomy. A significant body of research exists on DCA, with a number of groups evaluating a number of different approaches including standard navigation [1-3], patient specific templates [4-6] and robotics [7-13].

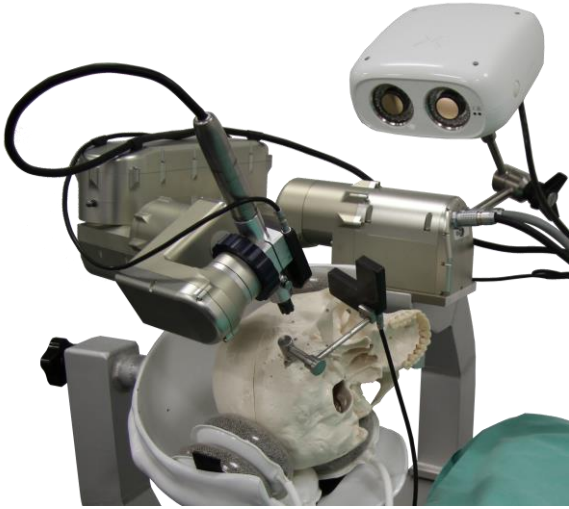
### B. Robot Assisted Cochleostomy

The cochleostomy is a key component in many cochlear implantation procedures. The technique involves the penetration of the outer bone tissue of the cochlea in order to expose the scala in preparation for insertion of a cochlear electrode array. Surgical performance of a cochleostomy presents a number of challenges: conventionally the process is completed manually using a hand held drill while working under a microscope. The cochlear is accessed either from the promontory exposed through the ear canal or from its basal turn through a mastoidectomy. In either approach it is necessary to reach the desired position at the cochlea with precision to drill the access, minimize trauma caused by mechanical disturbance and avoid overrun into the scala and subsequent perforation of the fragile endosteal membrane. By avoiding penetration of the endosteum, debris produced when drilling the access hole can be removed and sterile conditions preserved. Furthermore, accurate cochleostomy placement can have profound effects on the intra-cochlear anatomy post insertion, with incorrect placement potentially leading to damage of the basilar membrane or other structures upon insertion [14].

## II. MATERIALS AND METHODS

### A. Minimally invasive cochlear access

A robotic system, shown in Figure 1, was designed specifically for minimally invasive cochlear implantation procedures. The lightweight (5.5 kg), 5 degree of freedom robotic arm can be mounted directly to the side rails of a standard OR table with a dedicated robot mount, which includes a non-invasive patient fixation mechanism for minimization of patient movement. A force torque sensor is fitted at the robot wrist, enabling haptic control, semi-automatic registration and measurement of drilling process variables.



**Figure 1:** Robotic system for minimally invasive cochlear implantation.

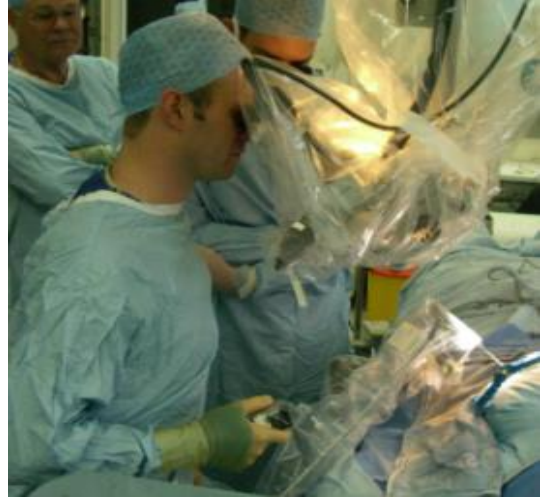
A commercially available high accuracy tracking system (CamBar B1, Axios3d, Germany) is integrated into the robot control software; the tracking system is used in combination with custom active tracking markers for visual servoing control. Finally, custom drilling tools and a self-developed drill hand piece provide increased accuracy through reduced tool bending (increased tool stiffness) and reduced backlash. The safety of the robotic procedure is ensured through the integration of additional sensor sources, including position information obtained from the correlation of drilling force and mastoid density, and functional information through integrated facial nerve monitoring.

The system also includes a dedicated planning software, which guides the surgeon through each of the steps required to plan a minimally invasive CI procedure. Fiducial screws and important anatomical structures are segmented by the user with the aid automatic and semi-automatic segmentation tools [15]. Once the structures have been defined, the surgeon can then plan a trajectory which avoids these.

Assessment of the feasibility of minimally invasive cochlear implantation was completed in an in-vitro cadaver study, described in detail in [16]. A total of eight temporal bone specimens underwent the full proposed clinical workflow as well as an additional post-operative evaluation step. The accuracy of the robotic system was assessed through the co-registration of pre- and post-operative images; the drilled

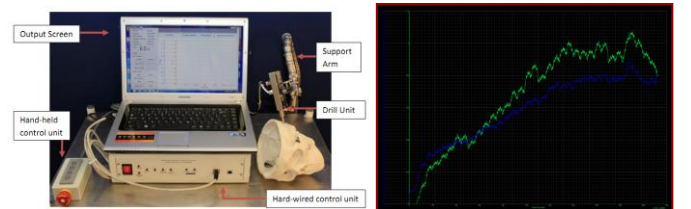
tunnel was segmented and compared to the planned position of the tunnel at the entrance position on the mastoid and at the planned target position. Additionally, the time required for the completion of each step was recorded. Note that the target in all eight cases was the round window; no cochleostomy was completed.

### B. Robot Assisted Cochleostomy



**Figure 2:** Robotic drilling of a cochleostomy.

A system with the ability to discriminate tissue and changes in tissue composition ahead on the drilling trajectory was developed for the completion of cochleostomy procedures [17]. The system consists of linear and rotational drives to feed and rotate standard surgical burs. This system is then attached to a flex lock arm, permitting free movement and stabilization of the drill. The burr is advanced onto the surface of the cochlea and the autonomous process of breaking through the bone tissue to expose the endosteum through a window of specific diameter begins. The drilling is entirely controlled through a hardwired control unit with the surgeon retaining executive control. Autonomous perception of critical phenomena and structures is completed using the coupled force and torque drilling transients in real-time (Figure 2). This enables automated selection of appropriate control strategies to achieve a precise and consistent result with respect to the flexible tissues. The most important responsibility of the system is to prepare the window on the endosteum without penetration.



**Figure 3:** The micro-drilling system for controlling exposure of the endosteum without penetration uses force and torque transients to discriminate the state of tissue-tool interaction.

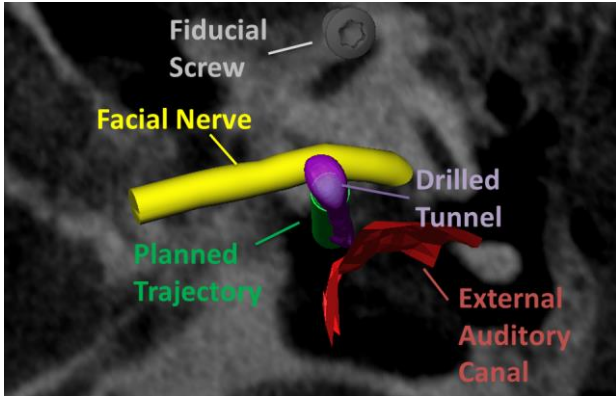
The controller analyses the force and torque imparted onto the drill bit in real time (Figure 3) to discriminate the state of the

tissue-tool point interaction from which actuation strategies are selected.

The robotic tool was comprehensively tested in pre-clinical porcine and cadaver studies, as well as being used in the operating theater for the performance of sensor guided cochleostomy.

### III. RESULTS

#### A. Minimally invasive cochlear access

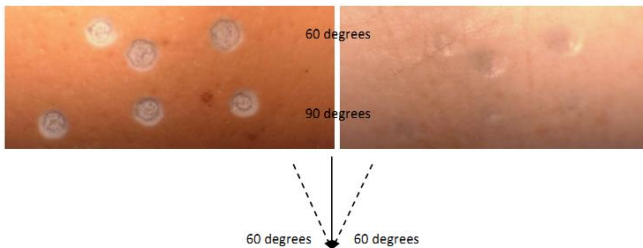


**Figure 4:** Post-operative analysis of drilling accuracy.

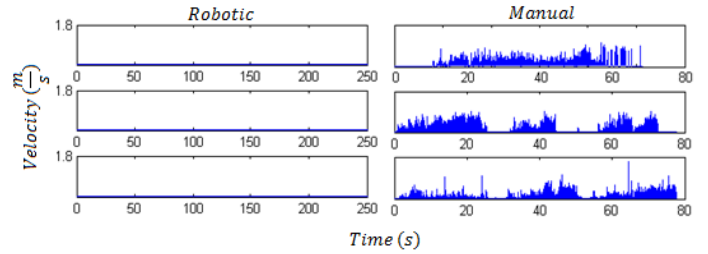
The robotic system allowed minimally invasive inner ear access without damage to surrounding anatomy in all cases. An accuracy of  $0.08 \pm 0.05$  mm was observed at the surface of the mastoid; an accuracy of  $0.15 \pm 0.08$  mm was observed at the planned target. Full electrode insertion through the round window approach was achieved in seven of eight cases: in a single case two electrode pairs remained outside of the cochlea. The setup of the robotic system took on average 7.1 minutes; positioning of the patient and fixation of the reference tracking marker an average of 4.6 minutes; patient to image registration approximately 3 minutes. The drilling, performed in 3 stages, required an average of 6 minutes to complete. The total procedure took, on average, approximately 21 minutes. Anatomy segmentation and trajectory planning was completed in less than 20 minutes in all cases.

#### B. Robot Assisted Cochleostomy

The system allows information about the state of the drilling process to be extracted from observed force and torque data; subsequently drill breakthrough can be predicted and controlled, minimizing trauma to the inner ear. Laboratory investigations confirmed robustness of the techniques to different angles of incidence with tissue interfaces (Figure 5) and tissue thickness [18].



**Figure 5:** Robustness to angle of incidence of drilling trajectory (bone tissue and membrane aspects)



**Figure 6:** Intra-cochlear disturbance amplitude: robotic and manual drilling

Laser vibrometric measurements during cochleostomy demonstrated that the robotic approach produced only 1% of the peak disturbance amplitude of manual drilling (Figure 6) [19]. It was also shown that cochleostomies were uniform and that the endosteum remained intact. The results indicate that using the robotic drill reduces trauma within the cochlea and that the approach for detection is robust and consistent when subjected to a wide variation of operating and tissue conditions.

### IV. DISCUSSION

Comprehensive pre-clinical validation of the image guided robotic system for minimally invasive cochlear access has established an overall accuracy sufficient for the safe completion of the procedure. In addition to being highly accurate, the system has been designed with eventual clinical integration in mind. Additionally, novel safety features based on alternative sensor sources provide an additional level of safety on top of the high accuracy workflow. The autonomous system for cochleostomy is able to penetrate the cochlear while leaving the endosteal membrane intact, thus maintaining sterility and avoiding the influx of debris. A decrease in complications, as well as increased retention of residual hearing, is expected as a result of this approach compared with conventional methods

Recent debate about the best route for cochlear electrode insertion (round window or cochleostomy) stems mostly from the desire for clinicians to retain residual hearing loss by minimizing intra-cochlear damage during the insertion process. Most literature advocates a round window approach when possible due to the increased trauma associated with the manual drilling process [20-23]. The robotic systems described within have proven successful in allowing both minimally invasive access to the cochlea and trauma free cochleostomy for electrode insertion. The combination of these two complimentary approaches will allow safe and reliable execution of the cochleostomy procedure, as well as highly accurate placement of the cochleostomy site, potentially leading to decreased trauma during insertion and increased retention of residual hearing.

### REFERENCES

- [1] J. Schipper, A. Aschendorff, I. Arapakis, T. Klenzner, C. B. Teszler, G. J. Ridder, and R. Laszig, "Navigation as a quality management tool in cochlear implant surgery.," *The Journal of laryngology and otology*, vol. 118, no. 10, pp. 764–70, Oct. 2004.
- [2] R. F. Labadie, P. Chodhury, E. Cetinkaya, R. Balachandran, D. S. Haynes, M. R. Fenlon, A. S. Jusczyck, and J. M. Fitzpatrick, "Minimally invasive, image-guided, facial-recess approach to the middle ear: demonstration of the concept of percutaneous cochlear access in vitro.," *Otology & neurotology: official publication of the American*

Otological Society, American Neurotology Society [and] European Academy of Otology and Neurotology, vol. 26, no. 4, pp. 557–62, Jul. 2005.

- [3] O. Majdani, S. H. Bartling, M. Leinung, T. Stöver, M. Lenarz, C. Dullin, and T. Lenarz, “[Image-guided minimal-invasive cochlear implantation-experiments on cadavers].,” *Laryngo- rhino- otologie*, vol. 87, no. 1, pp. 18–22, Jan. 2008.
- [4] R. F. Labadie, J. Mitchell, R. Balachandran, and J. M. Fitzpatrick, “Customized, rapid-production microstereotactic table for surgical targeting: description of concept and in vitro validation.,” *International journal of computer assisted radiology and surgery*, vol. 4, no. 3, pp. 273–80, May 2009.
- [5] R. Balachandran, J. E. Mitchell, G. Blachon, J. H. Noble, B. M. Dawant, J. M. Fitzpatrick, and R. F. Labadie, “Percutaneous cochlear implant drilling via customized frames: an in vitro study.,” *Otolaryngology-head and neck surgery: official journal of American Academy of Otolaryngology-Head and Neck Surgery*, vol. 142, no. 3, pp. 421–6, Mar. 2010.
- [6] R. F. Labadie, R. Balachandran, J. E. Mitchell, J. H. Noble, O. Majdani, D. S. Haynes, M. L. Bennett, B. M. Dawant, and J. M. Fitzpatrick, “Clinical validation study of percutaneous cochlear access using patient-customized microstereotactic frames.,” *Otology & neurotology: official publication of the American Otological Society, American Neurotology Society [and] European Academy of Otology and Neurotology*, vol. 31, no. 1, pp. 94–9, Jan. 2010.
- [7] C. J. Coulson, A. P. Reid, D. W. Proops, and P. N. Brett, “ENT challenges at the small scale.,” *The international journal of medical robotics + computer assisted surgery : MRCAS*, vol. 3, no. 2, pp. 91–6, Jun. 2007.
- [8] H. Eilers, S. Baron, T. Ortmaier, and B. Heimann, “Navigated , robot assisted drilling of a minimally invasive cochlear access,” *Communication*, no. April, 2009.
- [9] S. Baron, H. Eilers, B. Munske, J. L. Toennies, R. Balachandran, R. F. Labadie, T. Ortmaier, and R. J. Webster, “Percutaneous inner-ear access via an image-guided industrial robot system,” *Proceedings of the Institution of Mechanical Engineers, Part H: Journal of Engineering in Medicine*, vol. 224, no. 5, pp. 633–649, May 2010.
- [10] T. Klenzner, C. C. Ngan, F. B. Knapp, H. Knoop, J. Kromeier, A. Aschendorff, E. Papastathopoulos, J. Raczkowski, H. Wörn, and J. Schipper, “New strategies for high precision surgery of the temporal bone using a robotic approach for cochlear implantation.,” *European archives of oto-rhino-laryngology : official journal of the European Federation of Oto-Rhino-Laryngological Societies (EUFOS) : affiliated with the German Society for Oto-Rhino-Laryngology - Head and Neck Surgery*, vol. 266, no. 7, pp. 955–60, Jul. 2009.
- [11] L. B. Kratchman, G. S. Blachon, T. J. Withrow, R. Balachandran, R. F. Labadie, and R. J. Webster, “Design of a bone-attached parallel robot for percutaneous cochlear implantation.,” *IEEE transactions on bio-medical engineering*, vol. 58, no. 10, pp. 2904–10, Oct. 2011.
- [12] J.-P. Kobler, J. Kotlarski, J. Oltjen, S. Baron, and T. Ortmaier, “Design and analysis of a head-mounted parallel kinematic device for skull surgery.,” *International journal of computer assisted radiology and surgery*, vol. 7, no. 1, pp. 137–49, Jan. 2012.
- [13] B. Bell, C. Stieger, N. Gerber, A. Arnold, C. Nauer, V. Hamacher, M. Kompis, L. Nolte, M. Caversaccio, and S. Weber, “A self-developed and constructed robot for minimally invasive cochlear implantation.,” *Acta oto-laryngologica*, pp. 1–6, Mar. 2012.
- [14] R.J. Briggs, M. Tykocinski, K. Stidham, J.B. Roberson, “Cochleostomy site: implications for electrode placement and hearing preservation.,” *Acta Oto-Laryngologica*, 2005 Aug;125(8):870-6.
- [15] N. Gerber, B. Bell, M. Kompis, C. Stieger, M. Caversaccio, S. Weber, “A software tool for preoperative planning of implantable hearing devices.,” *International journal of computer assisted radiology and surgery*, vol. 7, no. 1, pp. 134-35, Jan. 2012.
- [16] B. Bell, N. Gerber, T. Williamson, K. A. Gavaghan, W. Wimmer, M. Caversaccio, and S. Weber, “In Vitro Accuracy Evaluation of Image-Guided Robot System for Direct Cochlear Access,” *Otology & Neurotology*, in print, 2013.
- [17] R. Taylor, X. Du, D. Proops, A. Reid, C. Coulson, and P.N. Brett, “A sensory-guided surgical micro-drill”, *Proc IMechE, Part C, Journal of Mechanical Engineering Science*, July 1, 2010, vol. 224, no. 7, pp. 1531-1537
- [18] X. Du, M.Z. Assadi, P.N. Brett, J. Dolton, D. Proops, and C. Coulson, “Robustness analysis of a smart surgical drill for cochleostomy”, *Int J Medical Robotics and Computer Assisted Surgery*, 2013 Mar, vol. 9, no. 1, pp. 119-26.
- [19] C. Coulson, M.Z. Assadi, X. Du, P.N. Brett, and D.Proops, “Smart micro-drill for cochleostomy formation: A comparison of cochlear disturbances with manual drilling and a human trial”, *Cochlear Implants International*, 2013 Mar, vol. 14, no. 2, pp. 98-106
- [20] S. Havenith, M.J Lammers, R.A. Tange, F. Trabalzini, A. Della Volpe, G.J. van der Heijden, W. Grolman, “Hearing preservation surgery: cochleostomy or round window approach? A systematic review.,” *Otology & Neurotology*, 2013 Jun;34(4):667-74
- [21] R.J. Briggs, M. Tykocinski, J. Xu, F. Risi, M. Svehla, R. Cowan, T. Stover, P. Erfurt, T. Lenarz, “Comparison of round window and cochleostomy approaches with a prototype hearing preservation electrode.,” *Audiology & Neuro-otology*, 2006;11 Suppl 1:42-8.
- [22] C. Richard, J.N. Fayad, J. Doherty, F.H. Linthicum Jr., “Round window versus cochleostomy technique in cochlear implantation: histologic findings.,” *Otology & Neurotology*, 2012 Sep;33(7):1181-7
- [23] D.A. Gudis, M. Montes, D.C. Bigelow, M.J. Ruckenstein, “The round window: is it the "cochleostomy" of choice? Experience in 130 consecutive cochlear implants.,” *Otology & Neurotology*, 2012 Dec;33(9):1497-501